



Miami-Dade County
Medical Examiner Department
Number One on Bob Hope Road
Miami, FL 33136
Phone (305) 545-2400 Fax (305) 545-2418



REVOLTE, ELORD

ME CASE #:2015-02488

August 05, 1998

17 Years

Black

Male

DATE:09/01/2015

4563 Gulfstream Road , West Palm Beach, Florida ,

TYPE:ME

PLACE OF DEATH: Jackson Health Systems

Time of Death: 31-Aug-2015 11:17 pm

Investigating Agency: Miami-Dade Police Department PD150901326506 Det. Andino

Incident Location: 3300 NW 27 Avenue , Miami, Florida 33142

Incident Date / Time: Scene Dr.:

TERMINAL EVENT: According to the initial information received, the decedent was an inmate at the Juvenile Justice Department. On August 30th, 2015, he became involved in a physical altercation with another inmate. There were no emergency services summoned to administer any treatment, after this incident. On August 31, 2015, the decedent complained of stomach and chest pains. He was transported to Jackson Health Services/Pediatrics Unit.

Hospital records (MRN #4560143) disclosed, the decedent arrived to the emergency department with chest and abdominal injury reportedly sustained during an assault which occurred on August 30th, 2015. The location of the injury to the chest is left chest wall medially. The location of injury to the abdomen is bilateral. There were associated symptoms of vomiting and head injury but, not an altered level of consciousness. The decedent reportedly suffered multiple blows to the head, chest, and abdomen on August 30th, 2015, when he was assaulted by multiple other men (reported as 18) in the facility where he was detained. Since then he has had abdominal pain, vomiting five times on today's date. He complained of mid epigastric and mid sternal pain. On August 31, 2015 at 10:40pm, nurses observed the deceased standing by a garbage can inside his room and pointing toward his throat. He had difficulty breathing, clear liquid and phlegm coming from his mouth. The Heimlich maneuver was performed and suction was done for the large amount of oral secretions. He began to lose his balance and fell into the arms of a nurse. He became stiff and unresponsive. He was placed on a stretcher and transferred to the resuscitation room. He was placed on cardiac monitor and advanced cardiac life support efforts were initiated. Physicians were unable to manually revive him. His condition deteriorated and on August 31, 2015 at 11:17pm, he was pronounced deceased by the hospital physician.

MEDICAL HISTORY: Information not made available.

MEDICATIONS: None

Cause of Death: Blunt Force Injury of Neck, and Chest

Due To:

Due To:

Due To:

Contributory Cause:

Manner: Homicide

Autopsy

09/01/2015

Doctor: Hurst, Sean M.D.

Mortuary: EMMANUEL-VILLA

Investigator: Ledesma, Yvonne

THIS REPORT MAY CONTAIN NON-VERIFIED INFORMATION AND
IS SUBJECT TO CHANGE

10/09/2015



Miami-Dade County
Medical Examiner Department
Number One on Bob Hope Road
Miami, FL 33136
Phone (305) 545-2400 Fax (305) 545-2418

MIAMI-DADE
COUNTY

REVOLTE, ELORD

August 05, 1998-

17 Years

Black

Male

ME CASE #:2015-02488

DATE:09/01/2015

TYPE:ME

4563 Gulfstream Road , West Palm Beach, Florida ,

PLACE OF DEATH: Jackson Health Systems

Time of Death:

31-Aug-2015 11:17 pm

Investigating Agency: Miami-Dade Police Department

Incident Location: 3300 NW 27 Avenue , Miami, Florida 33142

PD150901326506

Det. Andino

Incident Date / Time:

Scene Dr.:

SOCIAL HISTORY: According to the next of kin (father), the decedent was born in Haiti, but emigrated to the USA over 8 years ago. He was single and had no children. He did not smoke, drink or use illegal drugs. He was student at a local high school in Miami.

IDENTIFICATION: Method: Other Photo ID

By: Juvenile Justice Department

Relationship: Law Enforcement

Cause of Death: Blunt Force Injury of Neck, and Chest

Due To:

Due To:

Due To:

Contributory Cause:

Manner: Homicide

Mortuary: EMMANUEL-VILLA

Autopsy

09/01/2015


Doctor: Hurst, Sean M.D.

Investigator: Ledesma, Yvonne

CRFaceSheet rev0208

THIS REPORT MAY CONTAIN NON-VERIFIED INFORMATION AND
IS SUBJECT TO CHANGE

10/09/2015



MIAMI-DADE COUNTY
MEDICAL EXAMINER DEPARTMENT
Number One on Bob Hope Road
Miami, FL 33136
Phone (305) 545-2400 Fax (305) 545-2439



REVOLTE, ELORD
September 1, 2015... 8:30AM

Case No. 2015-02488

CAUSE OF DEATH:

Blunt Force Injury of Head, Neck, and Chest

Sean Hurst, M.D.
Associate Medical Examiner

Kenneth Hutchins, M.D.
Associate Medical Examiner

NOTE: The cause of death is based on the totality of the investigative data to date, which may not be included in the autopsy or external examination protocol.

THE MIAMI-DADE COUNTY MEDICAL EXAMINER DEPARTMENT, MIAMI, FLORIDA

REVOLTE, ELORD.....September 1, 2015... 8:30AM.....Case No. 2015-02488

AUTOPSY PROTOCOL

ATTENDEES:

FORENSIC TECHNICIAN: Karen Henryhand

PHOTOGRAPHER: Heidi Nichols

EXTERNAL EXAMINATION:

The body is that of a well-developed, well nourished, 5 foot 7 inch, 135 pound black man who appears the reported age of 17 years. The body is refrigerated, well-preserved, and unembalmed. A green plastic bracelet around the left ankle has the inscription "258640."

The scalp has curly, up to 0.3 centimeter, black hair in a normal distribution. The irides are brown. The corneas are clear. The pupils are each 4 millimeters in diameter. The sclerae are white. The inferior palpebral conjunctivae have rare petechiae. The nasal septum and nasal bones are intact. The facial bones are intact. The ears are unremarkable. The dentition is natural and in good repair. The mucosal surface of the right side of the upper lip has multiple, up to 0.3 x 0.2 centimeter abrasions. The frenula are intact.

The neck and chest are symmetrical. The nipples and breasts are unremarkable. The abdomen is soft and flat. The posterior torso is unremarkable.

The extremities have no fractures or deformities. The joints are not deformed. A 2 x 0.5 centimeter, raised, firm, black patch is on the left shoulder. The arms have no track marks. The wrists have no scars. An 8 centimeter linear scar is on the anterior medial aspect of the left thigh. Multiple, up to 0.5 centimeter round and linear scars are on the anterior aspect of the left leg. A 2 centimeter linear scar is on the anterior aspect of the right leg. The fingernails and toenails are intact.

The external genitalia are those of a fully developed, adult, circumcised man. The testes are palpable within the scrotal sac. The anus is unremarkable.

The body has no tattoos.

EVIDENCE OF MEDICAL INTERVENTION:

An endotracheal tube is in the mouth and terminates in the lower trachea.

Defibrillator pads are adhered to the right side of the chest and the left flank. Electrocardiogram pads are adhered to both sides the chest, the epigastric region, and the right upper quadrant of the abdomen.

A Foley catheter is in the urethra and terminates in the bladder.

A hospital identification bracelet is around the right wrist that includes the patient's name, date of birth, and medical record number.

THE MIAMI-DADE COUNTY MEDICAL EXAMINER DEPARTMENT, MIAMI, FLORIDA

REVOLTE, ELORD.....September 1, 2015... 8:30AM.....Case No. 2015-02488

AUTOPSY PROTOCOL

EVIDENCE OF INJURY:

BLUNT FORCE INJURY OF THE HEAD:

The left eye is swollen and there is an associated 2.5 centimeter ecchymosis over the medial aspect of the upper eyelid and multiple, up to 0.4 centimeter red abrasions on the lateral aspect of the upper eyelid. The right side of the face has a 2.5 x 3 centimeter, L-shaped red-brown abrasion. There are contusions of the mucosa of the lower lip.

The left parietal and occipital aspects of the scalp have subscalpular hemorrhages. The right temporal aspect of the scalp has a small amount of subscalpular hemorrhage.

BLUNT FORCE INJURIES OF THE NECK AND TORSO:

The right side of the neck has multiple, up to 3 centimeter, linear red-brown abrasions. Confluent, faint, purple contusion is on the anterior and left lateral aspects of the neck.

The soft tissues of the left shoulder and midline neck are hemorrhagic. The posterior aspects of the left sternocleidomastoid and left omohyoid muscles are hemorrhagic. The anterior and posterior surfaces of the sternohyoid and sternothyroid muscles are diffusely hemorrhagic. The deep soft tissues of the neck are hemorrhagic. The proximal left subclavian vein is lacerated.

Blood clot is adherent to the posterior surface of the sternum. The posterior insertions of the right first through eighth ribs and the left first through fifth ribs are hemorrhagic but they are not dislocated or fractured. There is associated intercostal hemorrhage.

Blood clot is adherent to both lobes of the thyroid gland. The trachea is encased in clotted blood. A small amount of blood clot is adherent to the hilum of the right lung and the lower lobe of the left lung. The left pleural cavity contains 1700 milliliters of liquid blood.

The anterior and posterior surfaces of the heart have focal petechiae. The anterior aspect of the proximal ascending aorta is hemorrhagic. The thoracic aorta is encased in clotted blood, but it is free of lacerations throughout its course. The left subclavian, left common carotid, brachiocephalic, right common carotid, and right subclavian arteries have adherent blood clot on the anterior surfaces but are intact and free of lacerations.

The left adrenal gland is hemorrhagic.

OTHER BLUNT FORCE INJURIES:

The posterior and lateral aspect of the right shoulder has multiple, up to 7 by 3.5 centimeter, dry, red abrasions.

THE MIAMI-DADE COUNTY MEDICAL EXAMINER DEPARTMENT, MIAMI, FLORIDA

REVOLTE, ELORD.....September 1, 2015... 8:30AM.....Case No. 2015-02488

AUTOPSY PROTOCOL

The fourth digit of the right hand has a 0.5 centimeter abrasion. The first digit of the left hand has a faint, 0.5 centimeter abrasion.

INTERNAL EXAMINATION:

The ribs, sternum, and clavicles are intact. The diaphragm is not elevated. The mesothelial surfaces are smooth and glistening. All body organs are in their normal anatomical positions. The right and left pleural cavities have no adhesions. The pericardial sac contains approximately 10 milliliters of yellow, serous fluid. The peritoneal cavity has no excess fluid or adhesions.

The soft tissues of the neck are injured as detailed above. The hyoid bone, thyroid cartilage, and larynx are intact. The tan-brown thyroid gland has a normal size and shape and unremarkable parenchyma.

The 340 gram heart has smooth epicardial surfaces and a normal amount of epicardial fat. The four cardiac chambers do not contain mural thrombi. The four thin, pliable cardiac valves have no deformities or vegetations and the valve circumferences are as follows: tricuspid – 12.5 centimeters, pulmonic – 7.1 centimeters, mitral – 10.4 centimeters, and aortic – 5.2 centimeters. The mural endocardium is thin, smooth, and translucent. The red-brown myocardium has no fibrosis, necrosis, erythema, or areas of accentuated softening or induration. The normally positioned ostia of the left main and right coronary arteries are patent. The coronary arteries arise normally and follow a right dominant distribution. The coronary arteries are thin-walled and patent throughout. The right and left ventricular free walls are 1.4 centimeters and 0.4 centimeters thick, respectively. The interventricular septum is 1.4 centimeters thick. The thin, elastic aorta is smooth and shiny with intimal fatty streaking and no atherosclerosis.

The upper airway is clear of debris and foreign material. The mucosal surfaces are smooth, pink-tan, and have small, focal petechial hemorrhages. The trachea and mainstem bronchi are clear of debris and foreign material. The right and left lungs are 330 and 230 grams, respectively. The pleural surfaces are smooth and glistening. The inflated, pink pulmonary parenchyma has no masses, granulomata, or discrete areas of consolidation. The pulmonary arteries are patent and have no thromboemboli. The bronchomediastinal lymph nodes are not enlarged.

The 1160 gram liver has a smooth, glistening, intact capsule covering dark brown parenchyma with a preserved lobular pattern and no focal lesions. The extra and intra hepatic vessels are patent. The gallbladder contains approximately 25 milliliters of dark green, mucoid bile and no calculi. The gallbladder mucosa is dark green and velvety. The common and hepatic bile ducts are patent.

The base of the tongue is unremarkable. The esophagus is lined by pink-tan, smooth mucosa and is not dilated or stenosed and has no varices. The stomach has a normal size and shape. The gastric mucosa is free of ulcerations and is arranged with the usual folds. There is a faint duodenal ulcer. The stomach contains approximately 100 milliliters of thin, black liquid. The small intestine is normal in length, configuration, and diameter and has a smooth, shiny serosal surface. The mucosa

THE MIAMI-DADE COUNTY MEDICAL EXAMINER DEPARTMENT, MIAMI, FLORIDA

REVOLTE, ELORD.....September 1, 2015... 8:30AM.....Case No. 2015-02488

AUTOPSY PROTOCOL

is free of ulcerations. The mesentery has a normal insertion. The large intestine has a smooth, shiny serosal surface and no palpable masses or obstructions. The appendix is unremarkable.

The pink-tan pancreas has an intact lobular architecture and patent duct.

The 80 gram spleen has an intact capsule covering red-purple parenchyma. The lymph nodes of the neck, chest, and pelvis are unremarkable. The mesenteric lymph nodes are enlarged up to 2 centimeters.

The right adrenal gland is unremarkable.

The right and left kidneys are 110 and 130 grams, respectively. The surfaces are smooth and red-brown. The parenchyma has well-defined corticomedullary junctions. The renal vessels are patent. The ureters have a normal course and caliber. The bladder contains 50 milliliters of yellow urine. The mucosa is tan, smooth, intact, and erythematous about the urethral orifice.

The prostate gland is unremarkable. The testes have homogeneous, yellow-tan parenchyma with no masses or ecchymoses.

The muscles skeletal system is well-developed. The muscles of the anterior neck, chest wall, abdomen, and iliopsoas are symmetrical, firm, and red-brown. The ribs, pelvic bones, and vertebral bodies of the cervical, thoracic, and lumbar spine are unremarkable.

The reflected scalp is injured as detailed above.

The skull is intact and has no fractures of the calvarium or skull base. There is no epidural or subdural hemorrhage.

The brain is 1210 grams. The leptomeninges are thin and transparent. There is no subarachnoid hemorrhage. The cerebral hemispheres are symmetrical. The structures at the base of the brain including cranial nerves and blood vessels are intact. The thin-walled arteries at the base of the brain have no berry aneurysms or other obvious abnormalities. The gray-white matter border is distinct. The deep white matter has no softening, nodules, or masses. The mammillary bodies are not shrunk or discolored. The dorsal cerebellar vermis is not atrophic. The symmetrical hippocampi are not shrunk, scarred, or ecchymotic. The atlanto-occipital ligaments and cervical spine are intact.

A layerwise posterior neck dissection shows no injury.

AUTOPSY FINDINGS:

1. Blunt force injuries of the head:
 - a. Swollen left eye with periorbital ecchymosis
 - b. Abrasions of the face

THE MIAMI-DADE COUNTY MEDICAL EXAMINER DEPARTMENT, MIAMI, FLORIDA


REVOLTE, ELORD.....September 1, 2015... 8:30AM.....Case No. 2015-02488

AUTOPSY PROTOCOL


- c. Bilateral subscalpular hemorrhages
- 2. Blunt force injuries of the neck and torso
 - a. Lacerated left subclavian vein
 - b. Large amount of blood clot in the soft tissues of the neck and adherent to the strap muscles, the esophagus, the trachea, the thyroid gland, the lungs, and the aorta
 - c. Liquid blood in the left pleural cavity (1700 mL)
 - d. Hemorrhages of the posterior articulations of multiple ribs and associated intercostal hemorrhages.
 - e. Hemorrhage of the left adrenal gland
- 3. Abrasions of the right shoulder and right and left hands.
- 4. Enlarged mesenteric lymph nodes

TISSUES SUBMITTED FOR HISTOLOGY INCLUDE THE FOLLOWING:

Heart, lung, liver, kidney, and lymph node




Sean Hurst, M.D.
Associate Medical Examiner



Kenneth Hutchins, M.D.
Associate Medical Examiner

Date: September 8, 2015



DADE COUNTY MEDICAL EXAMINER DEPARTMENT
NUMBER ONE ON BOB HOPE ROAD, MIAMI FL 33136-1133
TELEPHONE (305) 545-2400
FAX (305) 545-2418

AUTOPSY DICTATION

DR. Hurst / Autchins

DATE 9/1/2015

2015-2488
ME CASE #

Revelle, Elord
NAME

Homicide
MANNER

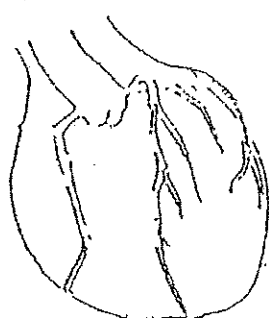
08:30
TIME

HT 340
RL 330
LL 230
L 1160

S 80
RK 110
LK 130
B 1210

AGE 17
RACE B
SEX M
HT 5'7"
WT 135

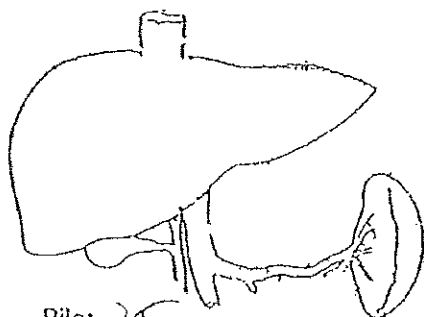
TOX ☒ or ☐
SCENE Y or ☒



LV - 1.4
RV - 0.4
V - 1.4

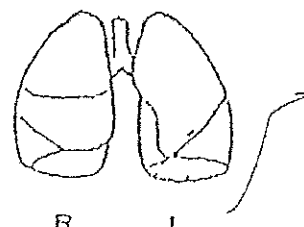


Dominant: Rt / Lt
Valve circumference
TV: 12.5 MV: 10.4 - PV: 7.1 AV: 5.2

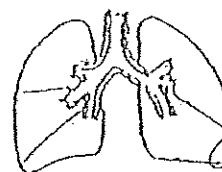


Bile: 25
Stomach content: 100
Urine volume: 58
Appendix: unremarkable

RESPIRATORY SYSTEM



1700 gms
Blood



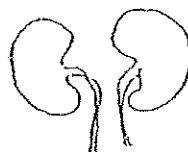on section + bronch
clot
mesenteric in up to

2 cm
Anterior - 4 cm - 0.5 x 0.5

L. Punctate / fist 3 cm
hem

R. P. Sinus / P. hem

Hem - fist R. b. 1.5 - 1
1.5 - 2

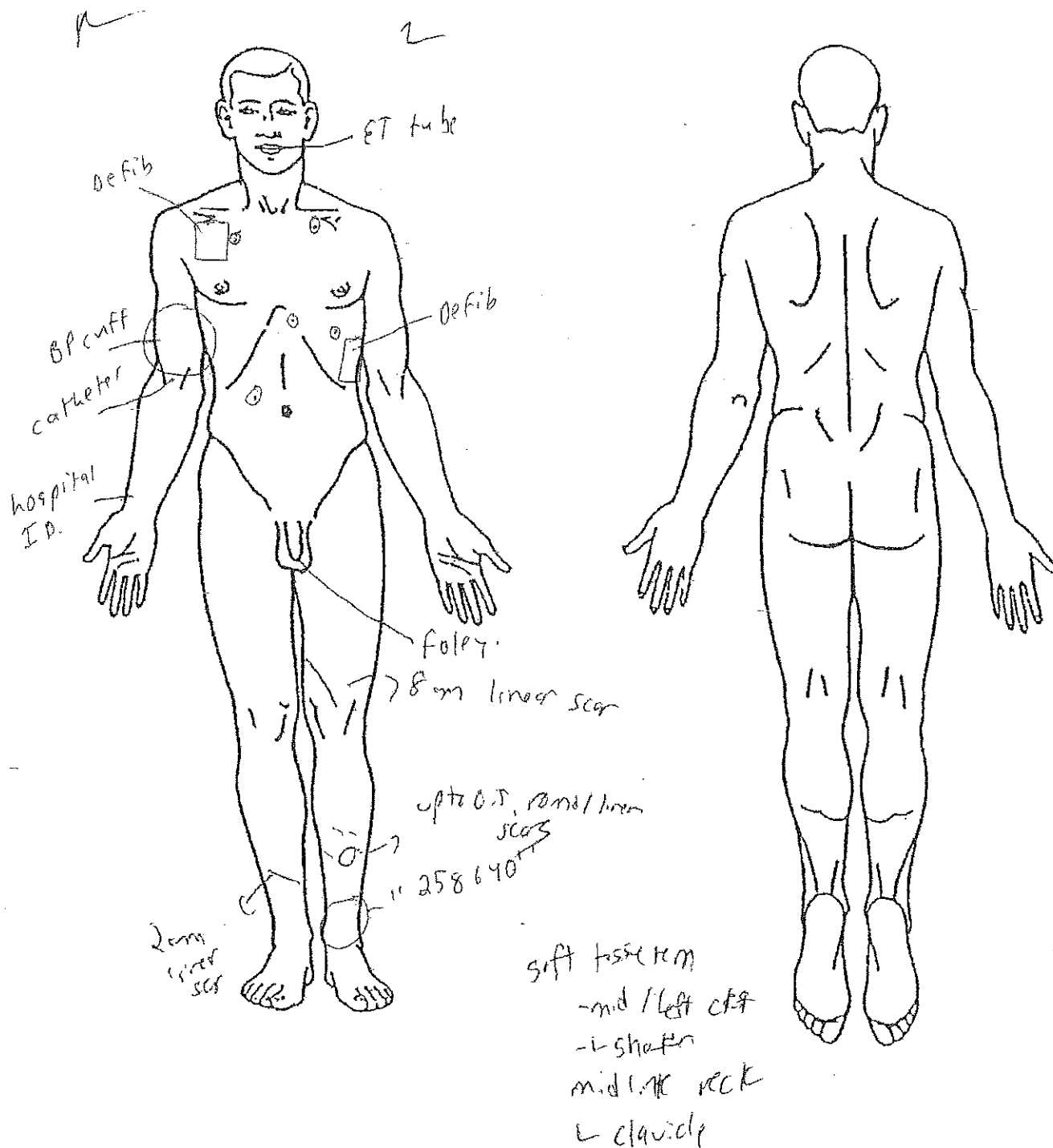


UB

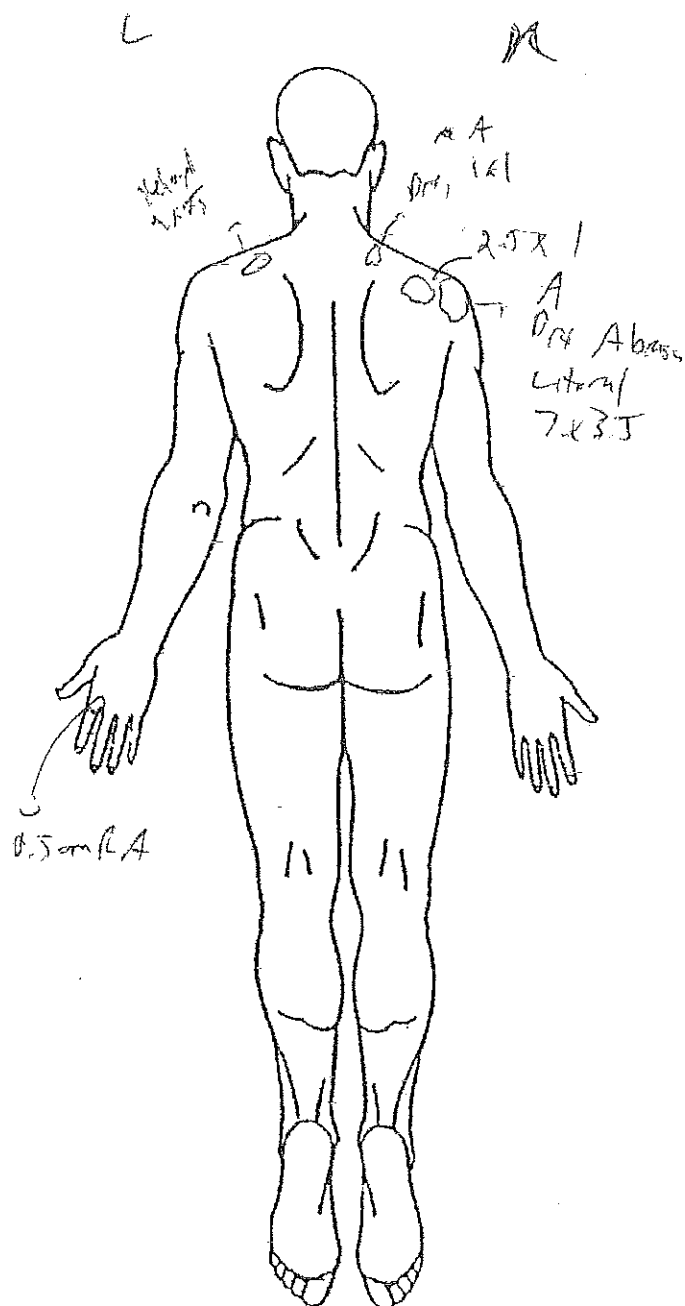


CASE NO. 2488 NAME Revolte

AGE 17 RACE B SEX M HEIGHT 5-7 WEIGHT 135



FORM A



0,5 cm LA

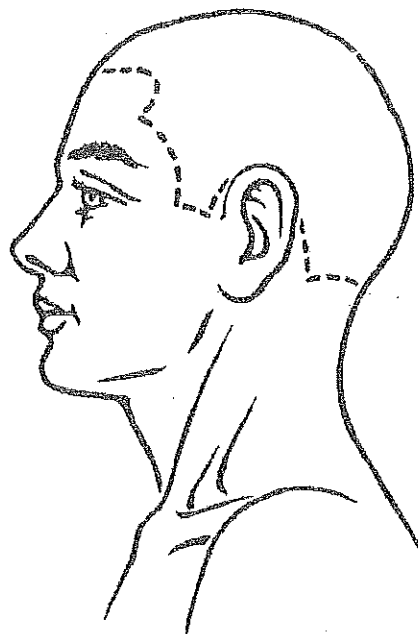
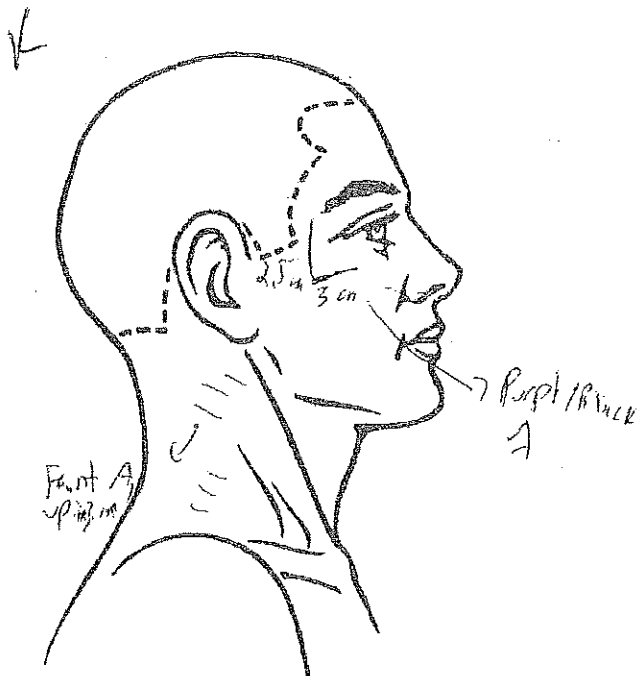
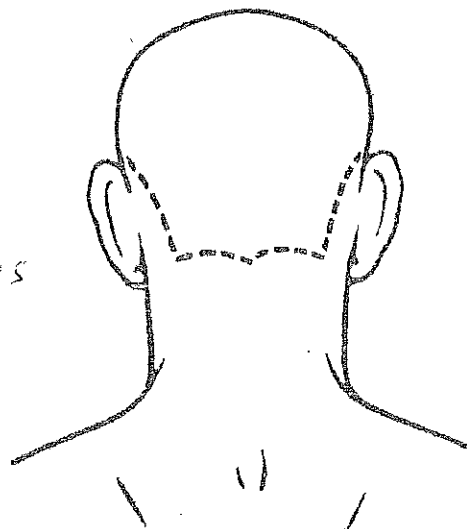
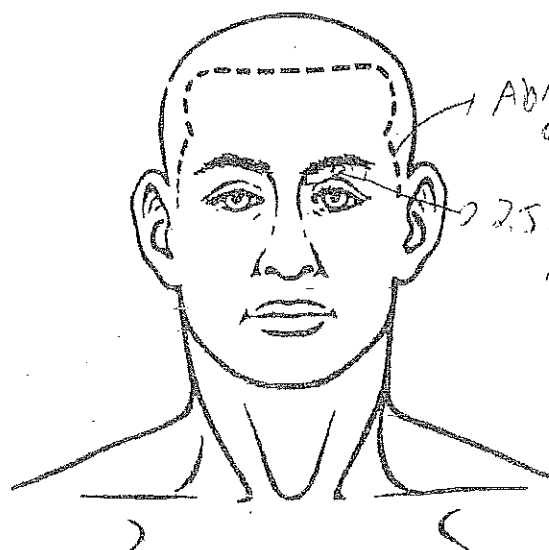



MIAMI-DADE COUNTY MEDICAL EXAMINER DEPARTMENT
NUMBER ONE ON BOB HOPE ROAD
MIAMI, FL 33136-1133

HEAD and FACE DIAGRAM

Name Revolt, Elord M.E. CASE NO. 2012-2488

L eye - swollen





**MIAMI-DADE COUNTY
MEDICAL EXAMINER DEPARTMENT**

Number One on Bob Hope Road
Miami, FL 33136
Phone (305) 545-2400 Fax (305) 545-2439



MICROSCOPIC REPORT

REVOLTE, ELORD

Case No. 2015-02488

HEART (2 sections): No significant microscopic abnormalities

LUNG (2 sections): The section of the left lung has no significant microscopic abnormalities and the section of the right lung has alveolar hemorrhage.

KIDNEY (2 sections): No significant microscopic abnormality


LIVER (1 section): No significant microscopic abnormality

MESENTERIC LYMPH NODE (1 section): Follicular hyperplasia. A section of the stomach is attached to the lymph node, which has no significant microscopic abnormalities.

**Sean Hurst, M.D.
Associate Medical Examiner**

**Kenneth D. Hutchins, M.D.
Associate Medical Examiner**

Date: 9/18/2015



**Miami-Dade County
Medical Examiner Department**

Number One on Bob Hope Road
Miami, FL 33136
Phone (305) 545-2400 Fax (305) 545-2418



CASE NOTES

ME Case #: 2015-02488

Decedent's Name: REVOLTE, ELORD

Date	Case Note By	Note
9/3/2015 12:27:00PM	Ledesma, Yvonne	Attorney Byrnes Guillaume 561 201 8350 representing the father Enoch Revolte on this case. SOCIAL HX: The decedent was born in Haiti and immigrated to the USA over 8years ago. He was single and had no children. He did not smoke, drink or use illegal drugs. He was student at a local high school in Miami. At this time, the attorney did not wish to answer any additional questions in regards to terminal event.
9/4/2015 12:03:00PM	Ledesma, Yvonne	Received call: Daniela Meus Child Protection Investigator for Dept of Children and Families. She stated, the decedent was in State of Florida Custody at the time of his demise. She believes he was a Ward of the State and charges of abandonment were filed against the father. The decedent's mother lives in Haiti and has received death notification. Ms. Meus has provided the following contact information for the Child Protection Team manager to verify the information and provide assistance as to final arrangements. Mr. Charles Scherer 305 992 9808 CPT case manager.
9/4/2015 12:05:00PM	Ledesma, Yvonne	This MDI discussed this case with investigation unit supervisor S. Tyler Luke who stated, the case will now require a COURT ORDER specifying who the ME Dept can release the remains to, therefore, a HOLD was placed on this case until further information is received.
9/10/2015 4:20:00PM	Ledesma, Yvonne	Court Order authorizing the decedent's father to complete final arrangements has been received. EMAIL sent to doctor Hurst requesting to remove the HOLD placed for this case.

ME#2015-02488

MIAMI-DADE COUNTY
PRELIMINARY POLICE DEATH INVESTIGATION REPORT
FOR THE MEDICAL EXAMINER
PLEASE PRINT ALL INFORMATION

Police Agency MDPD
Police Case Number PD150901-326506
Lead Detective C. ARZANO

11-01-83 10/08

Name of Deceased REVOLTE, ELORD First Middle

Age 17 Race B Sex M D.O.B. 08-05-1998 Social Security -

Address 3300 NW 27th Ave Home Phone Occupation IMMIGRANT WORKER Employer

Place of Death (Hospital, House Address, Etc.): IMMIGRANT WORKER City St Zip

Place of Injury (Address): Injury Occurred: M D Y Time M Found By: Address: Phone:

TIME OF DEATH: Occurred: M D Y Time M Identified By: DEPARTMENT OF JUSTICE Address: Phone:

Found: M D Y Time M Pronounced: M D Y Time M

Relationship: Address: Telephone: Identified By: DEPARTMENT OF JUSTICE Address: Phone:

Name and Telephone of Doctors and/or Hospitals That Attended Deceased During Life: N/A

Physical Examination of the Body (Position/Location of Body): 45720

Lividity: No ☒ Yes ☒ Body Heat: Warm ☐ Cool ☒ Cold ☐

Trauma: No ☐ Yes ☒ Rigor Mortis: Pull ☐ Partial ☒ Fading ☐ Advanced ☐

Describe Trauma: MINOR SCARS TO RT. Decomposition: None ☒ Slight ☐ Advanced ☐

If Weapon Used (Possible Type) N/A Valuables: Yes ☐ No ☒ Impounded By:

Medication to M.E.: No ☒ Yes ☐ Disposition of Clothing: ☐ Discard Not Needed ☐ Save-Hold/Dry as Evidence

Possible Contagious Disease: Unknown ☒ No ☐ Yes ☐ Rape Kit ☐ Do Not Wash ☐ Do Not Finger/Palm Print ☐

Other: 9-1-2015 4:15AM Do Not Undress ☐ Take Body Temp ☐ White Copy to Medical Examiner Department/Yellow Copy to Police Department

MIAMI-DADE COUNTY

ME#2015-02488

PRELIMINARY POLICE DEATH INVESTIGATION REPORT
FOR THE MEDICAL EXAMINER
Continuation Sheet

Police Case No. PD150901-226506
Name of Deceased BERNARDE, ELIOD

Medical Examiner at Scene?

Yes ☐

No ☒

Name

Time Medical Examiner Requested

M

Body Removal Requested

M

Time Medical Examiner Arrived

M

Body Removal Transport Arrived

M

The Lead Investigator is

ANDENO

Telephone Number

(305) 471-2400

This report prepared by

ANDENO

Investigator to be present at Autopsy?

No ☐

Yes ☒

PLEASE NOTE WHERE APPLICABLE: Use second sheet if needed-Scene Information to Follow: What happened just prior to death? Terminal Event-Medical/Social Information-Medications.

THE (D) WAS AN INMATE AT THE FLORIDA JUSTICE DEPARTMENT
THE (D) WAS INVOLVED IN A FIST FIGHT ON 8-30-15.
POLICE OR FIRE RESCUE WERE NOT CALLED.

ON 8-31-15 THE (D) COMPLAINED OF STOMACH & CHEST
PAIN. THE (D) WAS TRANSPORTED TO THE HOSPITAL IN A UNIT.
THE (D) WAS ANNOUNCED DECEASED BY DR. A. FIDRHO AT
11:17PM